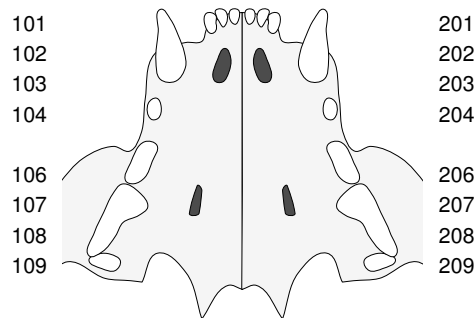
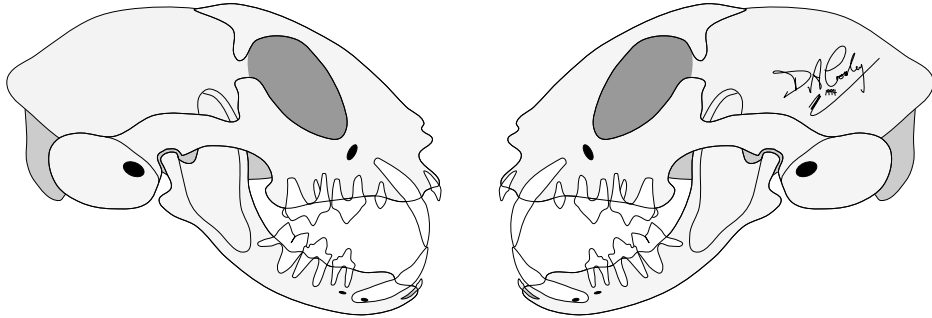
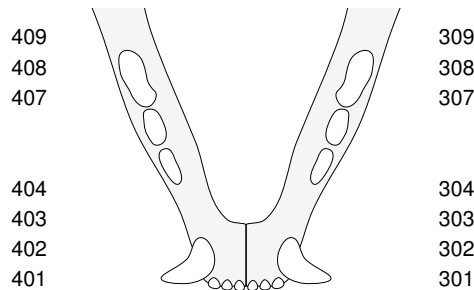


Feline dental assessment chart

Owner's name	Reference Code or Address				
Animal's name	Breed	Age	Sex	Weight	Date



RHS LHS



Key to abbreviations used

- # = Fracture
- + = Severity + to ++++
- m = Missing tooth
- = Tipping/positioning
- ↔ = Length relationship
- A = Abscess
- C = Cavity
- G = Gingivitis
- M = Mobility
- P = Periodontitis
- Pn = Pocket depth, mm
- R = Recession
- Rn = Depth in mm
- S = Supernumerary
- W = Wear
- X = Extracted

© 1995-2003 DaCross Services

Dental procedures

Assessment by quadrant

(graded +, ++, +++, ++++)

Performed	Required	Assessment by quadrant				
		1 (RU)	2 (LU)	3 (LL)	4 (RL)	
{ } Pre-anaesthetic checks	{ }	<i>Plaque</i>	:	:	:	:
{ } General anaesthesia	{ }	<i>Calculus</i>	:	:	:	:
{ } Radiography	{ }	<i>Gingivitis</i>	:	:	:	:
{ } Occlusal assessment	{ }	<i>Periodontitis</i>	:	:	:	:
{ } Supra-gingival scaling	{ }	<i>Occlusion</i>	:	:	:	:
{ } Subgingival scaling	{ }	<i>Tooth wear</i>	:	:	:	:
{ } Root planing	{ }	Other comments				
{ } Polishing	{ }					
{ } Gingival lavage	{ }					
{ } Gingival surgery	{ }					
{ } Extraction	{ }					
{ } Periodontal splinting	{ }					
{ } Crown height reduction	{ }					
{ } Endodontic therapy	{ }					
{ } Restoration	{ }					
{ } Orthodontic treatment	{ }					
{ } Oro-facial surgery	{ }					
Homecare program	{ ✓ }					

Routine Home Dental Care

The efficient daily use of a soft bristled toothbrush, with an appropriate animal toothpaste, is still the only proven method for long term control of plaque and gum disease.

Chewing exercise is beneficial as it stimulates natural tooth cleaning and protection mechanisms. In general hard chewing objects are not a good idea as many animals damage their teeth and gums on them, and swallowed pieces can cause serious problems. Avoid feeding soft sticky foods and never give items containing sugar or oil/fat as treats.

Specific Instructions